

CLINICAL PRACTICE

Acute Renal Colic from Ureteral Calculus

Joel M.H. Teichman, M.D.

This Journal feature begins with a case vignette highlighting a common clinical problem. Evidence supporting various strategies is then presented, followed by a review of formal guidelines, when they exist. The article ends with the author's clinical recommendations.

From the Division of Urology, University of British Columbia, and the Section of Urology, St. Paul's Hospital — both in Vancouver, B.C., Canada.

N Engl J Med 2004;350:684-93.
Copyright © 2004 Massachusetts Medical Society.

A 39-year-old man reports an eight-hour history of colicky pain in the right lower quadrant radiating to the tip of his penis. He had previously had a kidney stone, which passed spontaneously. Physical examination shows that he is in distress, is afebrile, and has tenderness of the right costovertebral angle and lower quadrant. Urinalysis shows microhematuria. Helical computed tomography (CT) of the abdomen and pelvis shows a 6-mm calculus of the right distal ureter and mild hydronephrosis. How should this patient be treated?

THE CLINICAL PROBLEM

Up to 12 percent of the population will have a urinary stone during their lifetime, and recurrence rates approach 50 percent.¹ In the United States, white men have the highest incidence of stones, followed in order by white women, black women, and black men.^{2,3} Fifty-five percent of those with recurrent stones have a family history of urolithiasis,⁴ and having such a history increases the risk of stones by a factor of three.⁵

The classic presentation of a renal stone is acute, colicky flank pain radiating to the groin. As the stone descends in the ureter, the pain may localize in the abdominal area overlying the stone and radiate to the gonad. Peritoneal signs are absent. As the stone approaches the ureterovesical junction (Fig. 1), lower-quadrant pain radiating to the tip of the urethra, urinary urgency and frequency, and dysuria are characteristic, mimicking the symptoms of bacterial cystitis. Physical examination typically shows a patient who is often writhing in distress, trying to find a comfortable position. Tenderness of the costovertebral angle or lower quadrant may be present. Gross or microscopic hematuria occurs in approximately 90 percent of patients; however, the absence of hematuria does not preclude the presence of stones.⁶

Owing to the shared splanchnic innervation of the renal capsule and intestines, hydronephrosis and distention of the renal capsule may produce nausea and vomiting. Thus, acute renal colic may mimic acute abdominal or pelvic conditions.

STRATEGIES AND EVIDENCE

DIAGNOSIS

The best imaging study to confirm the diagnosis of a urinary stone in a patient with acute flank pain is unenhanced, helical CT of the abdomen and pelvis (Fig. 1).⁷ In a prospective trial of 106 adults with acute flank pain, all patients underwent both unenhanced helical CT and intravenous urography (the previous gold standard),⁸ and the results of each were interpreted separately and in a blinded fashion by a radiologist. Seventy-five patients received a diagnosis of ureteral stones. The sensitivity of CT was 96 percent, as compared with 87 percent for urography, and the respective specificities were 100 percent and 94 percent ($P < 0.001$ for both comparisons). Positive and negative predictive

values were 100 percent and 91 percent, respectively, for CT, as compared with 97 percent and 74 percent, respectively, for urography. CT scans that were negative for stone disease revealed other abnormalities in 57 percent of patients, including appendicitis, pelvic inflammatory disease, diverticulitis, abdominal aortic aneurysm, and bladder cancer.⁷

When CT confirms the presence of a stone, a plain abdominal radiograph should be obtained to assess whether the stone is radiopaque. If CT is unavailable, plain abdominal radiography should be performed, since 75 to 90 percent of urinary calculi are radiopaque (Fig. 2). Although ultrasonography has high specificity (greater than 90 percent), its sensitivity is much lower than that of CT, typically in the range of 11 to 24 percent. Thus, ultrasonography is not used routinely but is appropriate as the initial imaging test when colic occurs during pregnancy.⁹

MANAGEMENT

Urgent Intervention

Urgent intervention is indicated in a patient with an obstructed, infected upper urinary tract, impending renal deterioration, intractable pain or vomiting, anuria, or high-grade obstruction of a solitary or transplanted kidney. Upper tract obstruction increases renal pelvic pressure, which reduces glomerular filtration and renal blood flow.¹⁰ Infection proximal to obstruction is suggested by fever, urinalysis showing pyuria and bacteriuria, and leukocytosis, and the presence of urosepsis is associated with an increased risk of complications. Impaired glomerular filtration inhibits the entry of antibiotics into the collecting system and requires emergency decompression by means of either percutaneous nephrostomy or ureteral stenting (Fig. 2 and 3).¹¹ The most common pathogen is *Escherichia coli*. Intravenous ampicillin and aminoglycoside provide broad antibiotic coverage, although oral fluoroquinolones may be a reasonable alternative; the type of antibiotic should be adjusted once the culture results are known. Infection proximal to an obstructing stone differs from a so-called infection stone (formed by urease-producing bacteria). Infection stones are made of struvite, tend to fill the entire collecting system (staghorn calculi), and are unlikely to pass into the ureter.

Pain and Nausea

The pain associated with ureteral stones has traditionally been managed with narcotics. Howev-

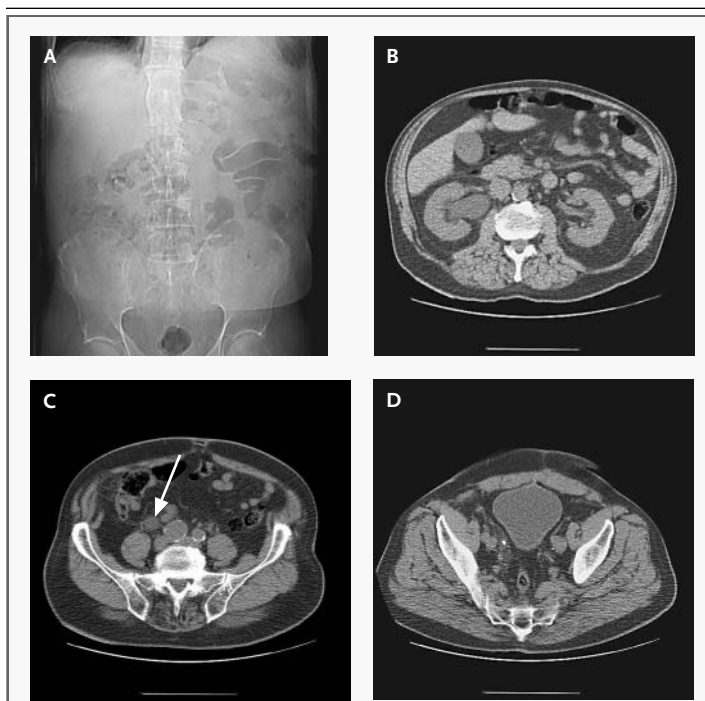

Figure 1. Plain Abdominal Radiography (Panel A) and Helical CT (Panels B, C, and D) in a 68-Year-Old Man with Nausea and Severe, Colicky Pain in the Right Lower Quadrant Radiating to the Tip of the Penis.

The plain abdominal radiograph shows a faint area of calcification just below the right sacroiliac joint (Panel A). Helical CT demonstrates right hydronephrosis (Panel B), right hydroureter (arrow in Panel C), and a 6-mm stone in the distal ureter (Panel D). The patient was treated with ureteroscopy, which showed stone impaction. The stone was 90 percent uric acid and 10 percent calcium oxalate.

er, nonsteroidal antiinflammatory drugs (NSAIDs) and cyclooxygenase-2 (COX-2) inhibitors also provide effective analgesia by blocking afferent arteriolar vasodilatation, thereby reducing diuresis, edema, and ureteral smooth-muscle stimulation.¹²⁻¹⁵ NSAIDs are less likely than narcotics to cause nausea. However, NSAIDs may further diminish renal function in patients with an obstruction, particularly those with preexisting renal impairment.^{16,17} Nonetheless, data indicate that in typical doses ketorolac — which is commonly used for colic — poses little risk of renal failure and does not increase the risk of surgical bleeding (Table 1).¹⁸ Although randomized, double-blind trials are lacking, ketorolac and diclofenac appear to be at least as effective as narcotics. When NSAIDs are used for acute renal colic, pain relief is achieved most rapidly by intravenous administration.^{12,13,15,19,20}

Renal colic may also be managed with the anti-

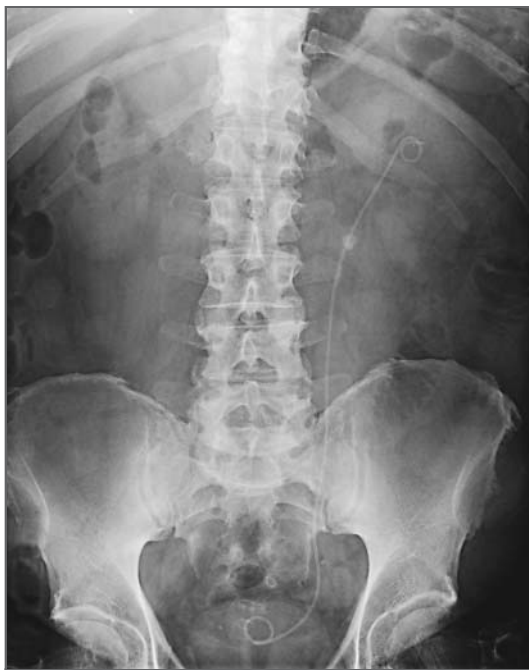

Figure 2. Abdominal Scout Film Showing a Stent and Ureteral Calculus in a 52-Year-Old Man Who Presented with Left-Flank Pain Radiating to the Lower Quadrant and Associated with Vomiting.

The stent was placed to decompress the upper tract, and the pain and vomiting resolved. The patient was treated unsuccessfully with shock-wave lithotripsy, followed by successful ureteroscopy.

diuretic desmopressin,^{14,17,21} although data on this approach are limited. If NSAIDs, COX-2 inhibitors, or desmopressin is used, overhydration should be avoided, since the objective of treatment is to reduce ureteral spasms.

Alternative approaches to pain relief have been less well studied. One randomized, prospective trial demonstrated that the pain from renal colic may be reduced by wrapping the patient's abdomen in a resistive heating blanket set to 42°C.²² Acupuncture may also reduce pain, but it has not been compared directly with commonly used medications.²³

Because the pain is due to renal capsular distention, intractable pain is controlled by decompressing the obstruction. In rare instances, patients may have intractable vomiting. These patients also require decompression and intravenous hydration.

Spontaneous Passage of the Stone

When urgent intervention is unnecessary, the clinician must decide whether to follow a patient expect-

antly for spontaneous stone passage or to perform an elective intervention. The likelihood of spontaneous stone passage decreases as the size of the stone increases (Table 2).^{24,26,27} The majority of stones that are less than 5 mm in diameter are likely to pass spontaneously.^{27,28}

Two thirds of the ureteral stones that pass spontaneously pass within four weeks after the onset of symptoms. The mean time to stone passage also increases as the size of the stone increases.²⁵ A ureteral stone that has not passed within one to two months is unlikely to pass spontaneously with continued observation.^{25,28} Furthermore, ureteral stones that are still symptomatic after four weeks have a complication rate of 20 percent (including renal deterioration, sepsis, and ureteral stricture).²⁶ Thus, observation for up to four weeks is generally reasonable if follow-up can be ensured.

Patients should be instructed to strain their urine and to submit the stone for composition analysis. Repeated imaging (plain abdominal radiography for radiopaque stones and CT for radiolucent stones) is warranted to confirm stone passage. If follow-up cannot be ensured or if follow-up imaging reveals no movement after a month, intervention is generally warranted.

Uric Acid Stones

The composition of the stone is rarely known at presentation, but uric acid stones may be suspected on the basis of a history of uric acid stones or of gout (which is present in approximately 20 percent of patients with uric acid stones).²⁹ The typical patient has normal amounts of uric acid in an acidic urine; this condition increases the likelihood of uric acid crystallization.³⁰ Pure uric acid calculi are radiolucent on plain imaging but visible on ultrasonography or CT. Other radiolucent stones that should be considered in appropriate clinical settings include matrix stones (which are made of organic material and are occasionally seen in patients with urease-producing bacteria) and indinavir stones.

Uric acid stones are unique in that they can be managed medically.³¹ At a urinary pH below 5.5, uric acid is poorly soluble; solubility increases at a pH above 6.5.³² Alkalinizing the urine with potassium citrate (or sodium citrate or sodium bicarbonate) dissolves pure uric acid stones.^{33,34} A standard therapy is 20 mmol of potassium citrate orally two to three times daily, with reassessment to verify adequate urinary alkalinization (to pH 6.5 to 7).

The time to dissolution varies with the size of

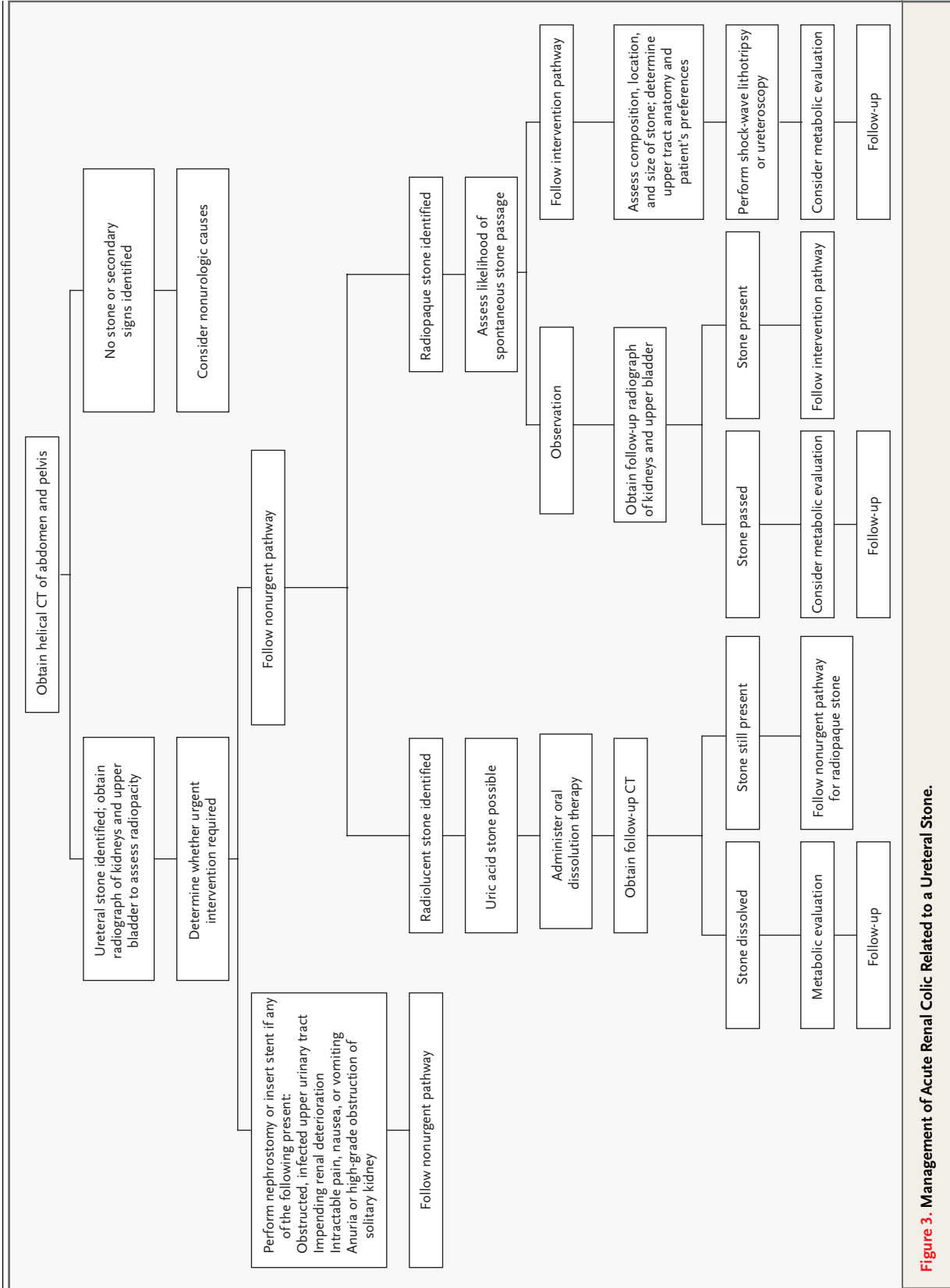


Figure 3. Management of Acute Renal Colic Related to a Ureteral Stone.

Table 1. Drugs Commonly Used to Treat Colic.*

Class and Name of Drug	Adult Dose	Adverse Effects	Contraindications
NSAIDs			
Ketorolac	30–60 mg IV or IM loading dose, then 15 mg IV or IM every 6 hr; oral continuation dose: 10 mg orally every 4–6 hr (maximum, 40 mg/day), not to exceed 5 days†	Common: dyspepsia, nausea, abdominal pain, diarrhea, headache, dizziness, elevated aminotransferase levels, drowsiness, tinnitus, pain at injection site Rare but serious: anaphylaxis, gastrointestinal bleeding, acute renal failure, bronchospasm, interstitial nephritis, Stevens–Johnson syndrome, agranulocytosis	Absolute: hypersensitivity, active peptic ulcer disease, cerebrovascular hemorrhage, breast-feeding, 3rd trimester of pregnancy Relative: advanced age, hypertension, congestive heart failure, nasal polyps, volume depletion
Diclofenac	50 mg orally 2 or 3 times/day	Thrombocytopenia; others similar to those of ketorolac	Similar to those for ketorolac
Cyclooxygenase-2 inhibitors			
Rofecoxib	50 mg/day	Common: diarrhea, hypertension, nausea, epigastric discomfort, peripheral edema, dyspepsia, fatigue, dizziness Rare but serious: gastrointestinal bleeding, esophagitis, hypersensitivity, bronchospasm, hypertension, congestive heart failure, potentially increased risk of myocardial infarction, hepatotoxicity, blood dyscrasias, renal failure	Absolute: hypersensitivity, NSAID-induced asthma, hepatic failure, renal failure, 3rd trimester of pregnancy, peptic ulcer disease, gastrointestinal bleeding Relative: renal failure, liver failure, hypertension, ischemic coronary artery disease, dehydration, congestive heart failure, fluid retention, advanced age
Narcotics			
Meperidine	1 mg/kg of body weight IM every 3–4 hr	Common: dizziness, lightheadedness, sedation, nausea, vomiting, dysphoria, dry mouth, urinary retention, hypotension, agitation, disorientation, constipation, flushing Rare but serious: respiratory depression, respiratory arrest, seizure, cardiac arrest, arrhythmia, shock	Absolute: hypersensitivity, use of monoamine oxidase inhibitors within 14 days Relative: advanced age, respiratory depression, seizure disorder, liver failure, renal failure, hypothyroidism
Morphine sulfate	0.1 mg/kg IM or IV every 4 hr	Biliary spasm, paralytic ileus, toxic megacolon, increased intracranial pressure, miosis, bradycardia; others similar to those of meperidine	Absolute: hypersensitivity, paralytic ileus Relative: chronic obstructive pulmonary disease, biliary disease, acute alcoholism
Narcotic combinations			
Acetaminophen with codeine	300 mg of acetaminophen with 30 mg of codeine, 2 tablets orally every 4–6 hr	Common: lightheadedness, sedation, dizziness, constipation, nausea, vomiting, hypotension, rash, biliary spasm, urinary retention, miosis Rare but serious: pancytopenia, thrombocytopenia, liver damage, respiratory depression, hemolytic anemia, neutropenia	Absolute: hypersensitivity Relative: glucose-6-phosphate dehydrogenase deficiency
Antidiuretics			
Desmopressin	40 µg/spray (if single dose ineffective after 30 min, consider NSAIDs or narcotics)	Common: headache, rhinitis, nausea, dizziness, epistaxis Rare but serious: hyponatremia, water intoxication, seizure, anaphylaxis, thrombosis	Absolute: type IIB von Willebrand's disease, hypersensitivity Relative: coronary artery disease, hypertension, hyponatremia, young age, advanced age, risk of thrombosis

* NSAIDs denotes nonsteroidal antiinflammatory drugs, IV intravenous, and IM intramuscularly.

† The dose is adjusted for patients older than 65 years and for those weighing less than 50 kg.

the stone and the extent of urinary alkalinization. A 2-cm uric acid stone bathed in urine with a constant pH of 7 takes approximately nine days to dissolve.³² Imaging can be repeated at one month to determine whether dissolution has occurred. Unless a stone is pure uric acid, however, oral dissolution therapy is not possible. If oral dissolution therapy fails, treatment should proceed as for a radiopaque stone.

AREAS OF UNCERTAINTY

TIMING OF ELECTIVE INTERVENTION

Although intervention is generally recommended after one month of observation, the optimal duration of observation is uncertain. In dogs with complete unilateral ureteral obstruction, irreversible renal deterioration begins at two weeks¹⁰; fortunately, ureteral stones rarely produce complete obstruction. Before the advent of helical CT (when intravenous urography was used to identify ureteral stones), observation for months was common in the absence of high-grade obstruction. One retrospective study evaluated 21 patients with ureteral stones that had been impacted for 2 to 48 months (a series of "worst-case" obstructions).³⁵ After stone removal, ureteral strictures developed in five patients (24 percent) after at least five months of impaction, but four of these patients had a history of iatrogenic ureteral perforation from failed intervention. In the other 16 patients, intravenous urography or nuclear-medicine studies were normal after stone removal. A longer duration of obstruction, a history of recurrent stone disease, and prior iatrogenic injury from manipulation are associated with an increased risk of renal impairment after stone passage.³⁶⁻³⁸

Whether nuclear renography is necessary to evaluate a patient for renal deterioration, and if so, how frequently it should be performed and what magnitude of change in function warrants intervention are matters of controversy.³⁹ Although CT is the best imaging test to use to diagnose a stone, it does not discriminate between severe and mild obstructions.⁴⁰

TYPE OF INTERVENTION

The ureter is divided anatomically into the proximal and distal portions (proximal and distal, respectively, to the iliac vessels). Shock-wave lithotripsy is generally used for proximal ureteral calculi that are 1 cm or smaller. The patient is positioned so that the stone lies at the focal point, where shock waves

converge and induce fragmentation. Machines have different shock-wave intensities (peak pressures) and focal volumes, and different machines result in different fragment sizes and re-treatment rates.⁴¹⁻⁴³ The desired outcome is the elimination of all stones (as assessed by repeated imaging). The presence of residual fragments increases the risk of further symptomatic episodes or re-treatment.⁴⁴ Stones made of calcium oxalate dihydrate or struvite fragment more effectively than stones made of calcium oxalate monohydrate, calcium phosphate (brushite), or cystine. However, the composition of a stone is rarely known before lithotripsy is performed. Recent data show that shock-wave lithotripsy is poor at fragmenting stones whose attenuation value on helical CT exceeds 1000 Hounsfield units, although further study is needed before the use of this measure can be recommended in practice.⁴⁵

Proximal ureteral stones that exceed 1 cm are treated more successfully by ureteroscopy than shock-wave lithotripsy.^{42,46} In a retrospective analysis of ureteral stones treated by either ureteroscopy or shock-wave lithotripsy (with the use of a Dornier DoLi machine), the stone-free rates for stones of 1 cm or greater were 93 percent and 50 percent, respectively.⁴⁶ For stones less than 1 cm, the stone-free rates did not differ significantly between the two groups (100 percent and 80 percent, respectively).

For distal ureteral calculi, the preferred treatment is controversial. In a randomized, prospective trial of patients with distal ureteral stones (mean size, 7 mm), shock-wave lithotripsy (with the use of an unmodified Dornier model HM3 machine) and ureteroscopy resulted in similar stone-free rates.⁴⁷ The percentage of patients who said they would repeat the procedure was slightly though not sig-

Table 2. Likelihood of Passage of Ureteral Stones.*

Size of Stone	Mean No. of Days Required to Pass Stone	Likelihood of Eventual Need for Intervention
		%
≤2 mm	8	3
3 mm	12	14
4–6 mm	22	50
>6 mm†	—	99

* Data were obtained from Hubner et al.²⁴ and Miller and Kane.²⁵

† A stone of this size is unlikely to be passed spontaneously.

nificantly greater for shock-wave lithotripsy (100 percent) than ureteroscopy (87 percent). Another study found that patients prefer shock-wave lithotripsy.⁴⁸

There has been concern that shock-wave lithotripsy might adversely affect ovarian function, although the limited available data have shown no obvious detrimental effect.^{49,50} Either this approach or ureteroscopy may be used in women of child-bearing age if not pregnant. Regardless of the mode of treatment used, the composition of all stones should be determined.

Ureteroscopy with use of the holmium:yttrium–aluminum–garnet (YAG) laser is effective for stones of all compositions and sizes.^{51,52} This technique involves passing the ureteroscope retrogradely through the urethra, bladder, and ureter to the stone under video guidance. The laser is delivered through a small-diameter fiber passed through the ureteroscope. The fiber tip touches the stone, the laser is

discharged, and the stone absorbs the laser’s energy, producing photothermal lithotripsy.⁵³ In a series of 504 patients treated with the use of this approach, stones were eliminated in 98 percent of those with distal ureteral calculi, 100 percent of those with middle ureteral calculi, and 97 percent of those with proximal ureteral calculi.⁵⁴ Ureteroscopy is less expensive than shock-wave lithotripsy,⁵⁵ but it is more time consuming and technically more demanding. In experienced hands, ureteroscopy is associated with a low risk of ureteral injury.

METABOLIC EVALUATION AND PROPHYLAXIS

Renal deterioration is more likely from recurrent than solitary episodes of ureteric stones.^{35,37} A patient with a recurrence of stones warrants a metabolic evaluation, although there is controversy regarding which tests are routinely indicated; the yield of testing and its effect on outcomes are uncertain. It is also controversial whether testing is indicated

Table 3. Metabolic Tests for Ureteral Stones.

Test	Ideal Candidate	Comments
Stone-composition analysis	All patients	
24-Hr urine collection for volume, pH, calcium, oxalate, uric acid, phosphate, sodium, citrate, creatinine, sulfate*	Patients with recurrent stones, those with a family history of stones, young patients, patients who request stone risk reduction	Sulfate measurement optional†; elevated urinary sulfate values suggest high intake of animal proteins, indicating possible need for dietary counseling to reduce intake of animal protein
24-Hr urine collection for volume, pH, creatinine, quantitative measurement of cystine*	Patients with cystine stones	Quantitative measurement of cystine guides titration of medications to reduce urinary cystine (e.g., tiopronin and penicillamine)
Measurement of serum calcium, potassium, bicarbonate, creatinine, blood urea nitrogen, chloride, uric acid	Patients with recurrent stones, those with a family history of stones, young patients,‡ patients who request stone risk reduction	High normal serum calcium and elevated serum calcium warrant parathyroid hormone and 1,25-dihydroxyvitamin D assays
Measurement of serum intact parathyroid hormone, 1,25-dihydroxyvitamin D	Patients with hypercalcemia (or serum calcium at high end of normal range)	Elevated serum calcium and parathyroid hormone suggestive of primary hyperparathyroidism; elevated serum calcium and vitamin D with suppressed parathyroid hormone suggestive of sarcoidosis
Urine culture and sensitivity	Patients with signs or symptoms of infection; those with alkaline urine; those with struvite stones	

* The 24-hour urine collection is generally obtained while the patient follows a random diet. A three-week delay is recommended after stone passage owing to concern that acute inflammation or bleeding may affect the results, although data on this risk are limited. Two 24-hour urine collections are often recommended, though this approach is controversial. If two are obtained, the second specimen should probably be collected while the patient follows a calcium-restricted diet^{59,60} (to identify whether hypercalciuria is dependent on dietary intake).

† Measurement of sulfate aids in the identification of a high intake of animal proteins, which may also be inferred from the dietary history.

‡ The risk of recurrence is assumed to be high for patients with a first stone before the age of 20 years and possibly for those with a first stone before the age of 30 years.

after a patient has a single stone. The same types of metabolic abnormalities are found among patients who have had a single stone and patients with recurrent stones, suggesting that early evaluation may be useful. An evaluation may be appropriate in patients with risk factors for a recurrence (such as a family history of stones or a young age).⁵⁶ Because the rate of compliance with long-term prophylaxis against stone formation, which entails any combination of changes in fluid intake and diet and the use of medications, is only 36 to 70 percent, a patient's potential compliance and motivation should be assessed before the metabolic evaluation.^{57,58}

Common metabolic tests are summarized in Table 3. The goal of these tests is to identify derangements that are amenable to intervention. Metabolic factors that increase the risk of recurrent stones include a low urinary volume (less than 2 liters daily), hypercalciuria (more than 250 mg of urinary calcium daily in women, more than 300 mg daily in men, or more than 4 mg per kilogram of body weight daily), and hypocitraturia (less than 320 mg of urinary citrate daily). These threshold values must be viewed cautiously, since solute concentration is a continuous variable. Even patients with apparently normal values might be at risk for a recurrence of stones if urinary output and solute concentration fluctuate.

A low urinary volume increases urinary supersaturation, so patients should be instructed to increase their fluid intake to achieve a urinary output of more than 2 liters per day. Because patients generally do not measure their urinary output, a simple instruction is for patients to drink enough fluids to maintain a clear-colored urine rather than a yellow urine. As they increase their fluid intake, patients should avoid increasing their sodium intake (for example, by drinking soft drinks), because this promotes natriuresis and hypercalciuria. Lemonade is a good beverage choice, since it reduces calcium oxalate supersaturation and increases urinary citrate.⁶¹ No study has compared lemonade with water, however, and the effects of drinking lemonade as a sole intervention against stone recurrence have not been reported.

Dietary calcium restriction alone is no longer recommended to reduce the risk of recurrence of calcium stones.⁶² A randomized, prospective trial showed a lower rate of recurrences among patients who restricted their intake of animal protein and salt than among those who restricted their calcium

intake.⁶³ A nonrandomized study of patients with absorptive hypercalciuria showed that restriction of both dietary calcium and oxalate, combined with treatment with a thiazide (2 to 4 mg of trichlormethiazide daily, 50 mg of hydrochlorothiazide daily, or 1.25 to 2.5 mg of indapamide daily) and potassium citrate (35 mmol daily) reduces urinary supersaturation and stone recurrence.⁶⁴ The relative benefits of dietary management, pharmacologic management, or the two in combination are uncertain. If other metabolic abnormalities are identified (for example, hyperoxaluria, distal renal tubular acidosis, primary hyperparathyroidism, hyperuricosuria, hypernitratemia, or sarcoidosis), appropriate therapy is warranted.⁶⁵

GUIDELINES

The American Urological Association published management guidelines for ureteral calculi in 1997 (they are available at http://www.auanet.org/timssnet/products/guidelines/main_reports/UreStnMain8_16.pdf).²⁸ These guidelines recommend that patients whose stones have a low probability of spontaneous passage (on the basis of their size and location) should be offered intervention. Shock-wave lithotripsy is considered first-line therapy for those with proximal ureteral stones of less than 1 cm. For proximal ureteral stones of 1 cm or larger, shock-wave lithotripsy, ureteroscopy, and percutaneous nephrolithotomy are all acceptable treatments. Either shock-wave lithotripsy or ureteroscopy is recommended for distal ureteral calculi.²⁸ These guidelines were written before the successful experience with ureteroscopy became widespread.⁵⁵

CONCLUSIONS AND RECOMMENDATIONS

Patients with ureteral calculi typically present with renal colic and hematuria. The unenhanced CT is the best diagnostic test. Pain control is important initially; I generally use ketorolac, although studies directly comparing ketorolac with other medications are lacking. Urgent intervention is indicated for a patient with an obstructed, infected upper urinary tract, impending renal deterioration, intractable pain or vomiting, anuria, or high-grade obstruction in a solitary or transplanted kidney (Fig. 3). In the absence of these factors, patients should be

followed closely for stone passage, with CT repeated after three to four weeks.

The patient described in the vignette has a 6-mm distal ureteral stone that is unlikely to pass spontaneously. He should be offered shock-wave lithotripsy or ureteroscopy. He had a prior stone and

should undergo metabolic evaluation, which I would recommend be performed three weeks after stone removal. To reduce the risk of stone recurrence, the patient should be encouraged to drink enough fluid to produce at least 2 liters of urine per day.

REFERENCES

- Sierakowski R, Finlayson B, Landes RR, Finlayson CD, Sierakowski N. The frequency of urolithiasis in hospital discharge diagnoses in the United States. *Invest Urol* 1978; 15:438-41.
- Soucic JM, Thun MJ, Coates RJ, McClellan W, Austin H. Demographics and geographic variability of kidney stones in the United States. *Kidney Int* 1994;46:893-9.
- Sarmina I, Spirnak JP, Resnick MI. Urinary lithiasis in the black population: an epidemiological study and review of the literature. *J Urol* 1987;138:14-7.
- Ljunghall S, Danielson BG, Fellstrom B, Holmgren K, Johansson G, Wikstrom B. Family history of renal stones in recurrent stone patients. *Br J Urol* 1985;57:370-4.
- Curhan GC, Willett WC, Rimm EB, Stampfer MJ. Family history and risk of kidney stones. *J Am Soc Nephrol* 1997;8:1568-73.
- Bove P, Kaplan D, Dalrymple N, et al. Reexamining the value of hematuria testing in patients with acute flank pain. *J Urol* 1999; 162:685-7.
- Vieweg J, Teh C, Freed K, et al. Unenhanced helical computerized tomography for the evaluation of patients with acute flank pain. *J Urol* 1998;160:679-84.
- Miller OF, Rineer SK, Reichard SR, et al. Prospective comparison of unenhanced spiral computed tomography and intravenous urogram in the evaluation of acute flank pain. *Urology* 1998;52:982-7.
- Shokeir AA, Mahran MR, Abdulmaaboud M. Renal colic in pregnant women: role of renal resistive index. *Urology* 2000;55:344-7.
- Vaughan ED Jr, Gillenwater JY. Recovery following complete chronic unilateral ureteral occlusion: functional, radiographic and pathologic alterations. *J Urol* 1971;106:27-35.
- Pearle MS, Pierce HL, Miller GL, et al. Optimal method of urgent decompression of the collecting system for obstruction and infection due to ureteral calculi. *J Urol* 1998; 160:1260-4.
- Cordell WH, Larson TA, Lingeman JE, et al. Indomethacin suppositories versus intravenously titrated morphine for the treatment of ureteral colic. *Ann Emerg Med* 1994; 23:262-9.
- Larkin GL, Peacock WF IV, Pearl SM, Blair GA, D'Amico F. Efficacy of ketorolac tromethamine versus meperidine in the ED treatment of acute renal colic. *Am J Emerg Med* 1999;17:6-10.
- Lopes T, Dias JS, Mercelino J, Varela J, Ribeiro S, Dias J. An assessment of the clinical efficacy of intranasal desmopressin spray in the treatment of renal colic. *BJU Int* 2001;87:322-5.
- Cordell WH, Wright SW, Wolfson AB, et al. Comparison of intravenous ketorolac, meperidine, and both (balanced analgesia) for renal colic. *Ann Emerg Med* 1996;28: 151-8.
- Brater DC. Effects of nonsteroidal anti-inflammatory drugs on renal function: focus on cyclooxygenase-2-selective inhibition. *Am J Med* 1999;107:65S-71S.
- Zabihi N, Teichman JMH. Dealing with the pain of renal colic. *Lancet* 2001;358: 437-8.
- Gillis JG, Brogden RN. Ketorolac: a reappraisal of its pharmacodynamic and pharmacokinetic properties and therapeutic use in pain management. *Drugs* 1997;53:139-88.
- Laerum E, Ommundsen OE, Gronseth JE, Christiansen A, Fagertun HE. Intramuscular diclofenac versus intravenous indomethacin in the treatment of acute renal colic. *Eur Urol* 1996;30:358-62.
- Tramer MR, Williams JE, Carroll D, Wiffen PJ, Moore RA, McQuay HJ. Comparing analgesic efficacy of non-steroidal anti-inflammatory drugs given by different routes in acute and chronic pain: a qualitative systematic review. *Acta Anaesthesiol Scand* 1998;42:71-9.
- el-Sherif AE, Salem M, Yahia H, al-Sharkawy WA, al-Sayrafi M. Treatment of renal colic by desmopressin intranasal spray and diclofenac sodium. *J Urol* 1995;153: 1395-8.
- Kober A, Dobrovits M, Djavan B, et al. Local active warming: an effective treatment for pain, anxiety and nausea caused by renal colic. *J Urol* 2003;170:741-4.
- Lee Y-H, Lee W-C, Chen M-T, Huang J-K, Chung C, Chang LS. Acupuncture in the treatment of renal colic. *J Urol* 1992;147: 16-8.
- Hubner WA, Irby P, Stoller ML. Natural history and current concepts for the treatment of small ureteral calculi. *Eur Urol* 1993; 24:172-6.
- Miller OF, Kane CJ. Time to stone passage for observed ureteral calculi: a guide for patient education. *J Urol* 1999;162:688-91.
- Ueno A, Kawamura T, Ogawa A, Takayasu H. Relation of spontaneous passage of ureteral calculi to size. *Urology* 1977;10: 544-6.
- Morse RM, Resnick MI. Ureteral calculi: natural history and treatment in an era of advanced technology. *J Urol* 1991;145:263-5.
- Segura JW, Preminger GM, Assimos DG, et al. Ureteral Stones Clinical Guidelines Panel summary report on the management of ureteral calculi. *J Urol* 1997;158: 1915-21.
- Yu TF, Gutman AB. Uric acid nephrolithiasis in gout: predisposing factors. *Ann Intern Med* 1967;67:1133-48.
- Sakhaee K, Adams-Huet B, Moe OW, Pak CY. Pathophysiologic basis for normouricosuric uric acid nephrolithiasis. *Kidney Int* 2002;62:971-9.
- Gutman AB, Yu TF. Uric acid nephrolithiasis. *Am J Med* 1968;45:756-79.
- Burns JR, Gauthier JF, Finlayson B. Dissolution kinetics of uric acid calculi. *J Urol* 1984;131:708-11.
- Pak CYC, Sakhaee K, Fuller C. Successful management of uric acid nephrolithiasis with potassium citrate. *Kidney Int* 1986;30: 422-8.
- Low RK, Stoller ML. Uric acid-related nephrolithiasis. *Urol Clin North Am* 1997; 24:135-48.
- Roberts WW, Cadeddu JA, Micali S, Kavoussi LR, Moore RG. Ureteral stricture formation after removal of impacted calculi. *J Urol* 1998;159:723-6.
- Andren-Sandberg A. Permanent impairment of renal function demonstrated by renographic follow-up in ureterolithiasis. *Scand J Urol Nephrol* 1983;17:81-4.
- Ala-Kulju K, Nummi P, Holst J. Conservative treatment of ureteric stones: ureteric stones — surgical intervention. *Ann Chir Gynaecol* 1985;74:284-7.
- Kelleher JP, Plail RO, Dave SM, Cunningham DA, Snell ME, Witherow RO. Sequential renography in acute urinary tract obstruction due to stone disease. *Br J Urol* 1991;67:125-8.
- Irving SO, Callega R, Lee F, Bullock KN, Wraight P, Doble A. Is the conservative management of ureteric calculi of >4 mm safe? *BJU Int* 2000;85:637-40.
- Bird VG, Gomez-Marin O, Leveillee RJ, Sfakianakis GN, Rivas LA, Amendola MA. A comparison of unenhanced helical computerized tomography findings and renal obstruction determined by furosemide ^{99m}Tc-mercaptoacetyltriglycine diuretic scintigraphy for patients with acute renal colic. *J Urol* 2002;167:1597-603.
- Teichman JMH, Portis AJ, Cecconi PP, et al. In vitro comparison of shock wave lithotripsy machines. *J Urol* 2000;164:1259-64.
- Cass AS. Comparison of first generation (Dornier HM3) and second generation (Medstone STS) lithotriptors: treatment results

- with 13,864 renal and ureteral calculi. *J Urol* 1995;153:588-92.
43. Graber SF, Danuser H, Hochreiter WW, Studer UE. A prospective randomized trial comparing 2 lithotriptors for stone disintegration and induced renal trauma. *J Urol* 2003;169:54-7.
44. Stroom SB, Yost A, Mascha E. Clinical implications of clinically insignificant stone fragments after extracorporeal shock wave lithotripsy. *J Urol* 1996;155:1186-90.
45. Joseph P, Mandal AK, Singh SK, Mandal P, Sankhwar SN, Sharma SK. Computerized tomography attenuation value of renal calculus: can it predict successful fragmentation of the calculus by extracorporeal shock wave lithotripsy? A preliminary study. *J Urol* 2002;167:1968-71.
46. Lam JS, Greene TD, Gupta M. Treatment of proximal ureteral calculi: holmium:YAG laser ureterolithotripsy versus extracorporeal shock wave lithotripsy. *J Urol* 2002;167:1972-6.
47. Pearle MS, Nadler R, Bercowsky E, et al. Prospective randomized trial comparing shock wave lithotripsy and ureteroscopy for management of distal ureteral calculi. *J Urol* 2001;166:1255-60.
48. Kuo RL, Aslan P, Abrahamse PH, Matchar DB, Preminger GM. Incorporation of patient preferences in the treatment of upper urinary tract calculi: a decision analytical view. *J Urol* 1999;162:1913-9.
49. Vieweg J, Weber HM, Miller K, Hautmann R. Female fertility following extracorporeal shock wave lithotripsy of distal ureteral calculi. *J Urol* 1992;148:1007-10.
50. Erturk E, Ptak AM, Monaghan J. Fertility measures in women after extracorporeal shockwave lithotripsy of distal ureteral stones. *J Endourol* 1997;11:315-7.
51. Teichman JMH, Vassar GJ, Bishoff JT, Bellman GC. Holmium:YAG lithotripsy yields smaller fragments than lithoclast, pulsed dye laser or electrohydraulic lithotripsy. *J Urol* 1998;159:17-23.
52. Teichman JMH, Rao RD, Rogenes VJ, Harris JM. Ureteroscopic management of ureteral calculi: electrohydraulic versus holmium:YAG lithotripsy. *J Urol* 1997;158:1357-61.
53. Vassar GJ, Chan KF, Teichman JMH, et al. Holmium:YAG lithotripsy: photothermal mechanism. *J Endourol* 1999;13:181-90.
54. Sofer M, Watterson JD, Wollin TA, Nott L, Razvi H, Denstedt JD. Holmium:YAG laser lithotripsy for upper urinary tract calculi in 598 patients. *J Urol* 2002;167:31-4.
55. Lotan Y, Gettman MT, Roehrborn CG, Cadeddu JA, Pearle MS. Management of ureteral calculi: a cost comparison and decision making analysis. *J Urol* 2002;167:1621-9.
56. Chandhoke PS. When is medical prophylaxis cost-effective for recurrent calcium stones? *J Urol* 2002;168:937-40.
57. Parks JH, Asplin JR, Coe FL. Patient adherence to long-term medical treatment of kidney stones. *J Urol* 2001;166:2057-60.
58. Van Drongelen J, Kiemeny LALM, Debruyne FMJ, de la Rosette JJMCH. Impact of urometabolic evaluation on prevention of urolithiasis: a retrospective study. *Urology* 1998;52:384-91.
59. Parks JH, Goldfisher E, Asplin JR, Coe FL. A single 24-hour urine collection is inadequate for the medical evaluation of nephrolithiasis. *J Urol* 2002;167:1607-12.
60. Yagisawa T, Chandhoke PS, Fan J. Comparison of comprehensive and limited metabolic evaluations in the treatment of patients with recurrent calcium urolithiasis. *J Urol* 1999;161:1449-52.
61. Seltzer MA, Low RK, McDonald M, Shami GS, Stoller ML. Dietary manipulation with lemonade to treat hypocitraturic calcium nephrolithiasis. *J Urol* 1996;156:907-9.
62. Curhan GC, Willett WC, Rimm EB, Stampfer MJ. A prospective study of dietary calcium and other nutrients and the risk of symptomatic kidney stones. *N Engl J Med* 1993;328:833-8.
63. Borghi L, Schianchi T, Meschi T, et al. Comparison of two diets for the prevention of recurrent stones in idiopathic hypercalciuria. *N Engl J Med* 2002;346:77-84.
64. Pak CYC, Heller HJ, Pearle MS, Odvina CV, Poindexter JR, Peterson RD. Prevention of stone formation and bone loss in adsorptive hypercalciuria by combined dietary and pharmacological interventions. *J Urol* 2003;169:465-9.
65. Goldfarb DS, Coe FL. Prevention of recurrent nephrolithiasis. *Am Fam Physician* 1999;60:2269-76.

Copyright © 2004 Massachusetts Medical Society.

POSTING PRESENTATIONS AT MEDICAL MEETINGS ON THE INTERNET

Posting an audio recording of an oral presentation at a medical meeting on the Internet, with selected slides from the presentation, will not be considered prior publication. This will allow students and physicians who are unable to attend the meeting to hear the presentation and view the slides. If there are any questions about this policy, authors should feel free to call the Journal's Editorial Offices.